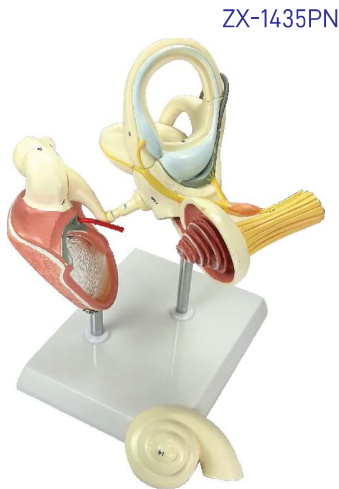

## E.N.T.

### ZX-1435PN Labyrinth with Ossicles (Middle Ear) Model

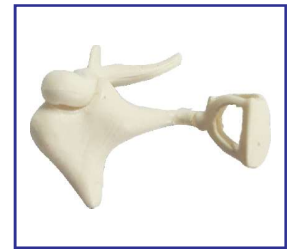

ZX-1435PN

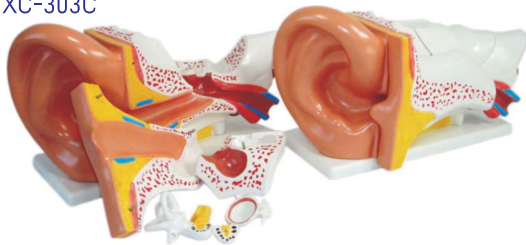- Size : 18 times enlarged
- Made of PVC
- Mounted on stand.
- Dissectable in 3 parts.
- 19 parts labeled in total.
- It shows the organs of the middle ear space and the inner ear.
- The membranous and bony labyrinths are shown.
- Cochlea can be opened.
- Well illustrated and informative.
- Beautifully painted in bright colors.
- Model is accurately made from actual specimen references, photographs and encyclopedia reference under expert guidance.
- Model is great teaching tool for anatomy lessons.
- Key card / Manual provided.

### ZX-1436 Auditory Bones, Enlarged

- Size : 3 times enlarged
- Made of PVC
- Natural colour
- Anatomically accurate and informative.
- Model is great teaching tool for anatomy lessons.
- Model is accurately made from actual specimen references, photographs and encyclopedia reference under expert guidance.
- Model shows 3 smallest bones located in middle ear, malleus (hammer), incus (anvil) and stapes (stirrup) joined to each other.
- Key card / Manual provided.



XC-303C

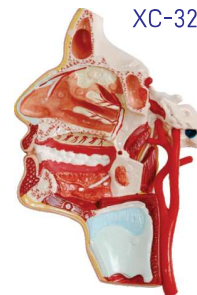

### XC-303C Ear Model New Style Giant Size

- Dissectable in 6 parts.
- Made of PVC Plastic.
- Size 33 x 15 x 23 cm.

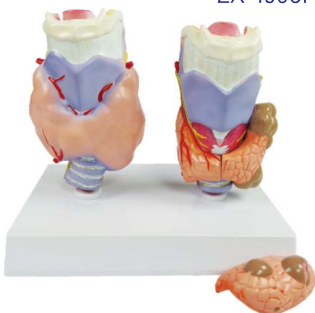
XC-324

### XC-324 Model of the Head



- This model shows the interior parts of the mouth cavity and pharynx with network of vessels & trigeminal nerves.

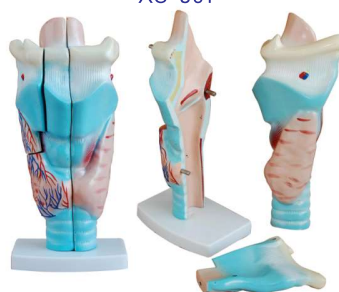ZX-1508P



### ZX-1508P Thyroid Diseases Model

- Life size
- Made of PVC
- Mounted on stand.
- Dissectable in 4 parts.
- It shows normal anatomy and common thyroid diseases.

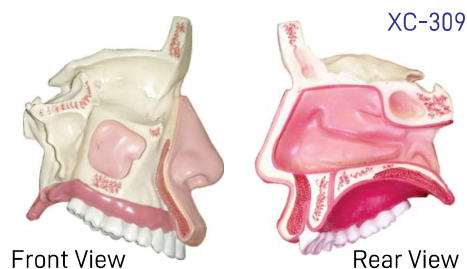
XC-301



### XC-301 Human Larynx Model Magnified

- Size 11.5 x 11 x 24 cm
- 3-parts dissectible.
- A functional model, On base 3 times enlarged.
- Shows movements of epiglottis & cartilages in the voice box.
- Shows the morphology and structure of the respiratory tract and phonetic organ.

XC-309



Front View

Rear View

### XC-309 Model of the Anatomical Nasal Cavity

- This model helps the students to understand:
- External nose : shows the section of the nasal bones and cartilages.
  - Nasal cavity : on the lateral nasal wall show the superior, middle and inferior nasal conchae project medially into the nasal cavity forming the superior, middle and inferior nasal maxillary sinuses.
  - Paranasal sinuses : shows the frontal, sphenoid and maxillary sinuses.